



Shoulder Arthroscopic Surgery

Shoulder Arthroscopic Surgery

1714 Milwaukee Ave.
Glenview, IL 60025
Phone: 847-699-6810
Fax: 847-699-6545
Website: www.ISMOC.net

Shoulder Arthroscopic Surgery

Definition of arthroscopy: Using a thin operating telescope to look into a joint. The joint is filled with saltwater and the arthroscope inserted. The arthroscope is less than a quarter-inch in diameter. It is inserted through a quarter-inch puncture in the joint. Other small instruments are inserted into the joint and surgical procedures are carried out through one or two other small punctures

Anesthesia: A general anesthetic (putting the patient to sleep) is used.

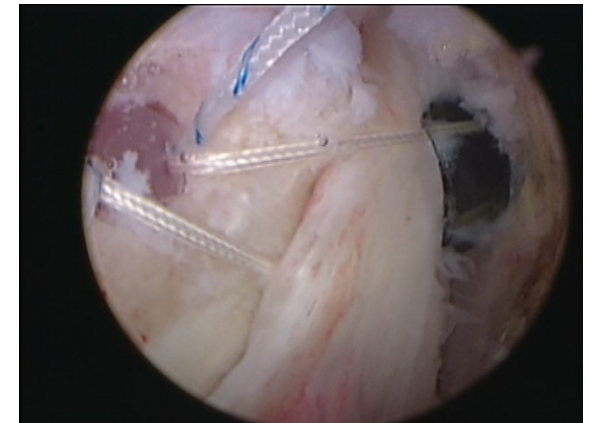
Risks and complications: Arthroscopic surgery is exceedingly safe. Nonetheless, it is not risk free. Infection and permanent nerve injury occur in less than one percent of cases. Stiffness requiring manipulation under anesthesia or necessitating the performance of a subsequent arthroscopic procedure may result. It is possible that symptoms may not be relieved, or if they are relieved, they may recur. A nerve problem called reflex sympathetic

dystrophy, although rare, could develop. This list is not exhaustive.

Rotator cuff procedures

Definition of rotator cuff tears: A sheet of four tendons that cover the top, front and back of the humeral head (the top of the arm bone at the shoulder). Its purpose is to hold the "ball" in the "socket" of the shoulder. The large shoulder muscles, the pectoral latissimus dorsi and deltoid, then move the arm wherever it needs to go. The supraspinatus is the rotator cuff muscle and tendon that sits atop the shoulder joint. In rotator cuff tears the supraspinatus is the principally injured tendon. The tears may extend backward into the infraspinatus, or forward into the

Arthroscopic Rotator Cuff Repair
During the arthroscopic surgery, sutures are inserted and then pulled tight to repair the torn rotator cuff .



subscapularis tendon. Rotator cuff tears cause pain and weakness of the shoulder.

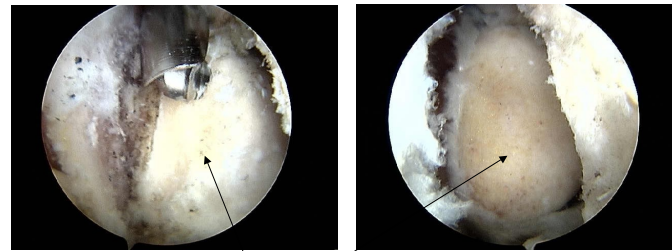
Diagnosis of rotator cuff tears:

Rotator cuff tears are usually seen on MRI and diagnosed using a combination of the MRI results and history and physical exam.

Rotator cuff repair: We perform this procedure arthroscopically. Surgery used to require a significant incision and overnight stay. Arthroscopic procedures are less painful and the recovery is quicker than with traditional open procedures. Small absorbable anchors are inserted into the shoulder and sutures attached to them are used to reattach the rotator cuff to the bone. Acromioplasty (see below) is usually performed at the same time.

Type of procedure: It is a minor procedure. Blood loss is negligible. The surgery is done on an outpatient basis in a hospital or surgicenter.

Distal clavicectomy



Arthritic tissue removed exposing healthy bone



Acromioplasty

Definition of acromioplasty: The acromion is the bone forming the roof of the shoulder. The undersurface of it often “impinges” on the rotator cuff. In acromioplasty the undersurface of the acromion is shaved to provide more room for the rotator cuff.



Resection of the Distal Clavicle

Definition of distal clavicectomy: This is an easily performed arthroscopic procedure. The distal clavicle forms part of the acromioclavicular or “A-C” joint. This is the joint at the top of the shoulder. It frequently becomes arthritic and painful. If injection fails to resolve the problem, resection of the distal clavicle is often the next step to relieve pain.

Type of procedure: Two or three ¼ - inch skin punctures are made and the arthroscope is inserted. A motorized burr is used to shave the end of the clavicle so that it will not rub and cause pain. The arm may be used for light activities immediately after surgery. Over the ensuing weeks as soreness decreases, function increases.



SLAP Lesions and Glenoid Labrum Repair

Definition of a SLAP lesion: The acronym stands for superior labral, anterior and posterior. The labrum is a washer-like border of cartilage that surrounds the shoulder joint. It also forms the root of the biceps tendon. The labrum can become partially detached from the top of the shoulder. This produces pain with activity. It often occurs after minor trauma.

Diagnosis: There is no definitive test to accurately tell the diagnosis in all cases. When MRI is used, a substance called “gadolinium” is injected into the shoulder before the MRI is taken. However, false negative and false positive tests are common. The history and physical exam, in conjunction with the MRI, help to zero in on the problem.

Treatment: If a SLAP lesion is suspected and rest and physical therapy have been unsuccessful in managing the problem, then arthroscopic evaluation is warranted. If the arthroscope picks up a SLAP lesion, it can be easily repaired at that time. The labrum is reattached with an absorbable anchor which is inserted and the labrum sutured to it. Complete healing and return to sports usually occur by six months after the procedure.

SLAP Lesion
Arthroscopic image of a typical SLAP lesion.

